

Monoclonal Antibody Treatment Exposes Three Mechanisms Underlying the Clinical Course of Multiple Sclerosis

Alasdair J. Coles, PhD,* Mark G. Wing, PhD,* Paul Molyneux, MRCP,† Andrea Paolillo, MD,† Charlie M. Davie, MD,† Geoff Hale, PhD,‡§ David Miller, MD,† Hermann Waldmann, PhD,§ and Alastair Compston, PhD*||

The elective treatment of patients with multiple sclerosis, using a humanized anti-leukocyte (CD52) monoclonal antibody (Campath-1H), has illuminated mechanisms that underlie the clinical course of the disease. Twenty-seven patients were studied clinically and by magnetic resonance imaging (MRI) before and for 18 months after a single pulse of Campath-1H. The first dose of monoclonal antibody was associated with a transient rehearsal of previous symptoms caused by the release of mediators that impede conduction at previously demyelinated sites; this effect remained despite selective blockade of tumor necrosis factor- α . Disease activity persisted for several weeks after treatment but thereafter radiological markers of cerebral inflammation were suppressed for at least 18 months during which there were no new symptoms or signs. However, about half the patients experienced progressive disability and increasing brain atrophy, attributable on the basis of MRI spectroscopy to axonal degeneration, which correlated with the extent of cerebral inflammation in the pretreatment phase. These data support the formulation that inflammation and demyelination are responsible for relapses of multiple sclerosis; that inflammatory mediators, but not tumor necrosis factor- α , cause symptomatic reactivation of previously demyelinated lesions; and that axonal degeneration, conditioned by prior inflammation but proceeding despite its suppression, contributes to the progressive phase of disability. These results provide evidence supporting the emerging view that treatment in multiple sclerosis must be given early in the course, before the consequences of inflammation are irretrievably established.

Coles AJ, Wing MG, Molyneux P, Paolillo A, Davie CM, Hale G, Miller D, Waldmann H, Compston A. Monoclonal antibody treatment exposes three mechanisms underlying the clinical course of multiple sclerosis. *Ann Neurol* 1999;46:296–304

The clinical course of multiple sclerosis is characterized by relapses with recovery, persistent neurological deficits, and progression. Not all these manifestations of the disease are attributable to demyelination and remyelination. Recovery from relapse is too rapid to be explained easily by remyelination, and it is difficult to explain the transition from relapsing–remitting disease to continuous progression of disability by demyelination alone. Here, we have exploited the opportunities of treating patients to study mechanisms underlying the clinical phenotype of multiple sclerosis. Previously, we treated 7 patients by using Campath-1H (Therapeutic Antibody Centre, Oxford, UK), a humanized monoclonal antibody that targets the CD52 antigen. Our rationale was the demonstration of long-term allograft acceptance in animals after pulsed therapy with

monoclonal antibodies targeting T cells.^{1,2} We demonstrated a reduction in MRI markers of cerebral inflammation for at least 6 months,³ thereby establishing proof of principle that sustained lymphocyte depletion is associated with suppression of new lesion formation in multiple sclerosis. However, our study suggested three issues of practical and theoretical importance for the treatment and understanding of multiple sclerosis.

First, during the initial dose of Campath-1H, patients experienced a systemic response accompanied by a transient and often severe, but invariably reversible, reactivation of previous neurological relapses that lasted for a few hours. We speculated that understanding the underlying mechanism of this effect might lead to insights into transient symptom production in multiple sclerosis in general. We established that Campath-1H

From the *University of Cambridge Neurology Unit, Addenbrooke's Hospital, and ||MRC Cambridge Centre for Brain Repair, University Forvie Site, Cambridge; ‡Therapeutic Antibody Centre, and §Sir William Dunn School of Pathology, Oxford; and †NMR Research Unit, Institute of Neurology, London, UK.

Received Oct 13, 1998, and in revised form Feb 5, 1999. Accepted for publication Mar 30, 1999.

Address correspondence to Dr Coles, University of Cambridge Neurology Unit, Box 165, Addenbrooke's Hospital, Hills Road, Cambridge CB2 2QQ, UK.

induced a coincident rise in serum tumor necrosis factor- α (TNF- α) and interferon- γ (IFN- γ).⁴ Several lines of evidence implicate TNF- α as the mediator of the first dose effect in other settings; ie, the systemic effect of OKT3, an anti-CD3 monoclonal antibody, can be blocked by CB006, an anti-human TNF- α antibody,⁵ and the hypothermia induced by anti-CD3 monoclonal antibody treatment of BALB/c mice is abolished by anti-TNF- α but not anti-IFN- γ antibodies.⁶ Accordingly, we investigated the contribution of TNF- α to the first dose effect of Campath-1H by *in vivo* TNF- α neutralization. Second, we tested the hypothesis, based on experimental work that the duration of effect of Campath-1H might be prolonged by the addition of a nondepleting anti-CD4 antibody. Third, we asked whether pulsed therapy would have an effect on clinical progression as well as on surrogate markers of cerebral inflammation.

This further study, using Campath-1H with a humanized monoclonal anti-CD4 antibody, soluble TNF- α receptor, and corticosteroids in randomized groups, extends our preliminary observations in an additional 28 patients with multiple sclerosis. All participants had secondary progressive multiple sclerosis and were selected by using clinical and radiological criteria to ensure that there would be active cerebral inflammation immediately before treatment was electively administered. We assessed clinical indices of activity and progression, and radiological markers of inflammation and tissue destruction for 3 months before and 18 months after lymphocyte depletion. Further information from quantitative MRI of these patients is reported in a complementary paper.^{6a}

Patients and Methods

Patients and Treatment

Patients were initially selected for treatment if they had clinically definite secondary progressive multiple sclerosis, historical evidence for a sustained deterioration in disability of at least one point in the Kurtzke expanded disability status scale (EDSS)⁷ over the preceding year, and at least one new enhancing lesion on a series of four monthly gadolinium-enhanced magnetic resonance scans. Of 130 patients screened, 50 fulfilled these clinical criteria, of whom 37 entered screening and 29 met the MRI entry criterion. Of these 29 patients, 1 was treated but later lost to follow-up and has therefore been excluded from the analysis. The remaining 28 patients were reviewed every 3 months and assessed by the same investigator on each occasion (A.J.C.); their mean age was 38.4 years, mean disease duration 12.5, and mean EDSS at entry was 5.4. The trial protocol was approved by the Local Research Ethics Committee (LREC 92/49). Radiological markers of tissue destruction were available in 27 patients.

All 29 patients received Campath-1H; 14 patients were randomized also subsequently to receive a humanized anti-CD4 antibody (Therapeutic Antibody Centre, Oxford, UK).

These two treatment groups were further divided into three arms, based on pretreatment of the first dose of Campath-1H; one cohort received nothing, the second was pretreated with methylprednisolone, and the third was given a soluble TNF- α receptor (a fusion protein of the two p55 TNF- α receptor domains and a human IgG1 constant region; Therapeutic Antibody Centre) before the initial dose of Campath-1H. There were therefore six different treatment schedules to which patients were randomized, with 5 patients in each group (except the cohort receiving soluble TNF- α receptor and anti-CD4, in which there was only 4). Each patient was given a total of 100 mg Campath-1H over 5 consecutive days, as a daily 20 mg infusion lasting 4 hours. A total of 200 mg of anti-CD4 antibody was given over the subsequent 5 days in 14 patients. Pretreatment in each group was either with methylprednisolone (500 mg), or soluble TNF- α receptor (4 mg), or nothing, given 30 minutes before the first dose of Campath-1H.

TNF- α Assays

Two enzyme-linked immunosorbent assays (ELISAs) were used to discriminate between free and bound TNF- α (data not shown). A commercial ELISA (R&D, Abingdon, UK) detected both free and bound TNF- α , whereas free TNF- α only was detected as follows: MicroELISA plates (96-well) (Dynatech M129B) were coated with anti-human TNF- α antibody (prepared from the 2-179-E11 hybridomas, 1 mg/ml, in carbonate-bicarbonate buffer, pH 9.6), and the TNF- α captured from sera samples was developed with polyclonal goat anti-TNF- α (R&D; 1:500), then anti-goat IgG antibody conjugated with alkaline phosphatase (Sigma, St Louis, MO; 2 mg/ml) and *p*-nitrophenol phosphate (Sigma; 1 mg/ml in diethanolamine buffer, pH 9.8), and the optical density read at 405 nm in an automated reader (Bio-Rad 3550). Standard curves were constructed by using logit-log transformations and levels of sensitivity determined as the lowest cytokine concentration at which the 95% confidence levels lay above the background optical density, which was 30 to 60 pg/ml. Bioactive TNF- α was measured by the cytotoxic effect of serum (at 1:20) on the L929 cell line.^{8,9} There was a considerable serum effect that disallowed absolute estimations of bioactive TNF- α concentrations; the results are shown as the cpm of incorporated ³H for sera taken at different times after Campath-1H, expressed as a percentage of the cpm induced by the pretreatment serum sample. Thus, a fall in the percentage represents an increase in bioactive TNF- α .

Magnetic Resonance Imaging

Scans were performed on a 1.5-T system (Signa; GE Medical Systems, Milwaukee, WI) according to a standard protocol.³ Patients had four scans monthly before treatment, then a further six scans monthly immediately after treatment. No imaging was performed between months 6 and 12 after Campath-1H; then patients had seven scans from months 12 to 18. The number of gadolinium-DTPA-enhancing lesions demonstrated on the first scan was recorded and the definition of disease activity confined to new enhancing lesions appearing on subsequent investigations; persistent enhancement in areas that had been active on the previous scan was

not counted as a new lesion. For statistical analysis, the study period was divided into five blocks of three informative scans (pretreatment and months 1–3, 4–6, 13–15, and 16–18 after treatment) and the total number of new enhancing lesions in these blocks was calculated for each patient. To compare activity in patients before and after treatment, we performed a two-tailed signed rank sum test on the logarithm of the ratio between the treatment and baseline blocks.

Brain volume was also derived from MRI scans. Having ensured acceptable repositioning between images, four contiguous slices from each scan were compared by an established technique¹⁰ and an estimate of the brain volume derived. Changes in cerebral volume between scans were accepted as significant if they fell outside the 95% confidence limits for measurement variation. Wilcoxon matched-pairs signed ranks were used for comparing volumes between groups and the Friedman test was used to compare cerebral volumes at different time points.

MRI spectroscopy was performed in patients and controls from a volume of normal appearing periventricular parietal white matter, ranging in size from 3.5 to 8 ml. This was compared with a voxel in the same region in an identical number of age-matched controls. Water-suppressed ¹H spectra were obtained by using a 90°–180°–180° sequence for volume selection and spectroscopic acquisition parameters of echo time (TE) 30 msec, repetition time (TR) 3,000 msec, with 192 averages collected in 10 minutes, using an eight-step phase cycle. Spectra were analyzed by using the LC Model method, which analyses the in vivo spectrum as a linear combination of a basis set of complete model spectra of metabolite solutions in the frequency domain in vitro and allows distinction between the *N*-acetyl aspartate (NAA) and *N*-acetylaspartyl glutamate components to the *N*-acetyl-derived spectra. Spearman's rank correlation test was used to test the data.

Results

Is the Acute Phase Effect of Campath-1H Caused by the Release of TNF- α ?

We randomized patients to receive an infusion of either methylprednisolone (500 mg), soluble TNF- α receptor (4 mg), or no additional therapy before the first dose of Campath-1H, to determine the contribution of TNF- α to the transient neurological deterioration seen with the first dose of Campath-1H. Corticosteroids and soluble TNF- α receptor each abolished the rise in serum TNF- α induced by Campath-1H measured in an ELISA for free TNF- α (Fig 1a); previous in vitro work had demonstrated that TNF- α recognized in this ELISA is bioactive in the L929 TNF- α assay (data not shown). However, an ELISA that also detected TNF- α bound to its receptor demonstrated the prolonged persistence of TNF- α receptor complexes in the circulation after soluble TNF- α receptor pretreatment (see Fig 1b); such complexes in vitro are not bioactive in the L929 assay (data not shown). That sufficient soluble TNF- α receptor was delivered is shown by experiments in which sera from patients after soluble TNF- α

receptor and Campath-1H therapy were shown to inactivate TNF- α in vitro (see Fig 1c).

The first dose of Campath-1H induced a syndrome of urticaria, pyrexia, and rigors. The neurological exacerbations experienced by patients lasted a few hours, were fully reversible, and consisted either of an exacerbation of existing deficits or the reawakening of previously experienced symptoms that may have been quiescent for several years. Corticosteroid pretreatment abolished the systemic response, the neurological deterioration, and the rise in serum cytokines induced by Campath-1H. However, although soluble TNF- α receptor effectively neutralized the rise in serum TNF- α , it had no impact on the extent or kinetics of the first dose effect after Campath-1H (Fig 2a and b). The neurological exacerbations induced by Campath-1H were not caused by de novo inflammation, as there was no change in gadolinium enhancement on MRI scans before and during the first dose of Campath-1H in 2 patients pretreated with soluble TNF- α receptor (data not shown).

Mechanisms underlying the expression of novel symptomatology in multiple sclerosis appear to differ from those that lead to rehearsal of previously experienced symptoms. Defining relapse as the appearance of any symptom or sign, including the exacerbation of preexisting manifestations, for 24 hours or more,¹¹ yielded a total of nine episodes in the treated group over the 3 months after treatment and 15 in the subsequent 18 months. This represents a significant reduction in the annualized relapse rate from 1.24 to 0.34 relapses per patient per year. However, all events experienced by treated patients beyond the first 2 months after Campath-1H consisted of a transient worsening of preexisting symptoms or signs, lasting no more than 3 days; no treated patient experienced a new clinical manifestations of multiple sclerosis during the period of follow-up (Fig 3a).

Does the Combined Use of Campath-1H and Anti-CD4 Modify the Effects of Lymphocyte Depletion?

The most sensitive marker of cerebral inflammation in multiple sclerosis is the number of gadolinium-enhancing lesions on MRI scans. Patients had monthly scans for 3 months before and 6 months after Campath-1H, followed by a further series of monthly scans at months 12 through 18 after treatment to assess the duration of effect. Compared with the 3-month period before Campath-1H, the number of enhancing magnetic resonance lesions was suppressed throughout the 18-month follow-up period—by 72% in the first 3 months after treatment, by 90% between months 3 and 6, by 66% over months 12 to 15, and by 71% in the final 3 months (see Fig 3b; $p < 0.001$). This trend was observed in every patient, but the absolute mean value of new enhancing lesions per scan is weighted by

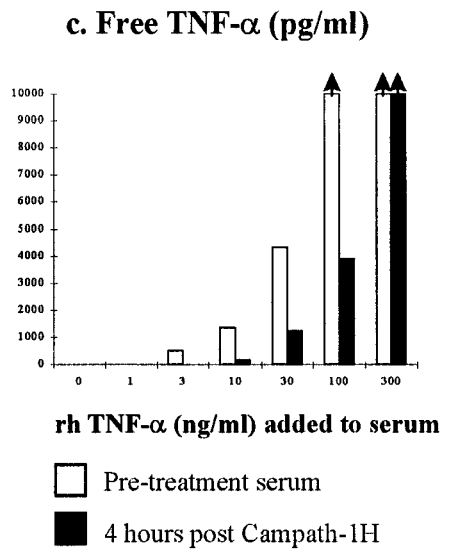
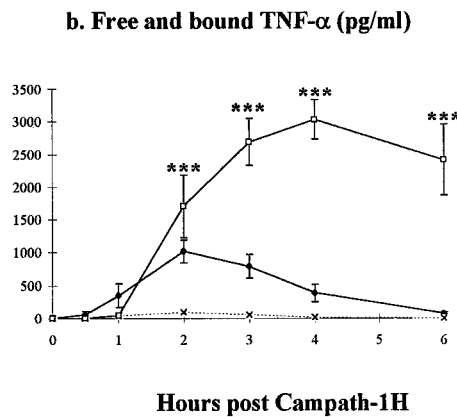
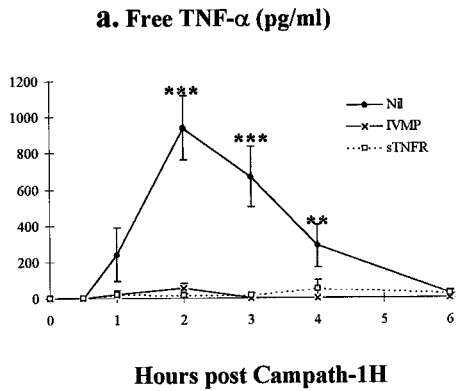


Fig 1. The effect of pretreatment with intravenous methylprednisolone (IVMP) or soluble tumor necrosis factor-α (TNF-α) receptor (sTNFR) on the rise in serum TNF-α induced by Campath-1H. (a) Free serum TNF-α. (b) Free and bound TNF-α both measured by enzyme-linked immunosorbent assay. (c) The dose-response curve of addition of recombinant human (rh) TNF-α in vitro to serum samples taken from patients before and after infusion of soluble TNF-α receptor and Campath-1H. Arrows indicate optical density readings above the maximum standard. **P < 0.01, ***P < 0.001. Nil = no pretreatment.

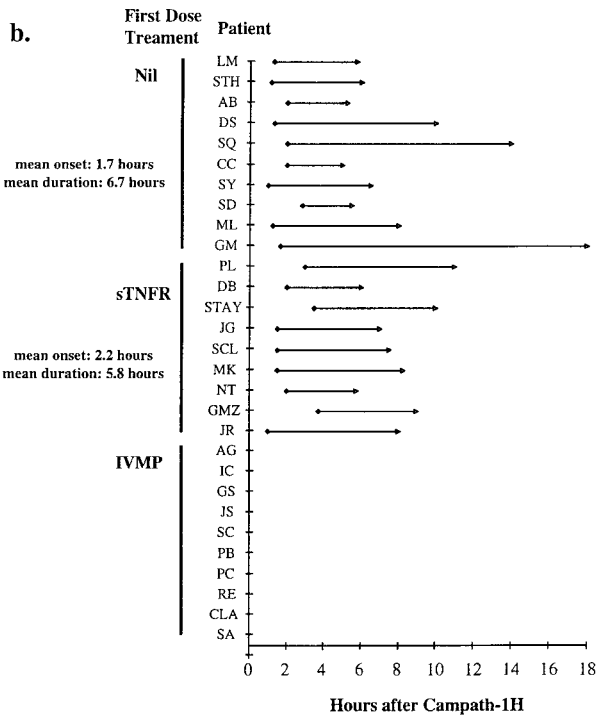
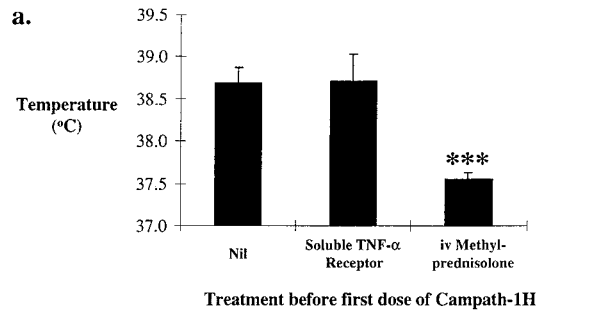


Fig 2. The effect of pretreatment with intravenous methylprednisolone (IVMP) or soluble tumor necrosis factor-α (TNF-α) receptor (sTNFR) on the clinical first dose effect of Campath-1H. (a) The maximum pyrexia induced by Campath-1H. (b) The neurological deterioration associated with the first dose of Campath-1H.

1 patient with 10 times more active disease before and after treatment. There was no significant difference in the number of enhancing lesions between patients in the different treatment groups either before or after treatment (data not shown) and the addition of anti-CD4 (together with the acute-phase manipulations listed above) conferred no advantage or deleterious effect on the suppression of new lesions.

Does Suppression of Inflammation Influence Disease Progression?

Defining progression of disability as an increase in the (Kurtzke) EDSS of 1 point over 3 months (or 0.5

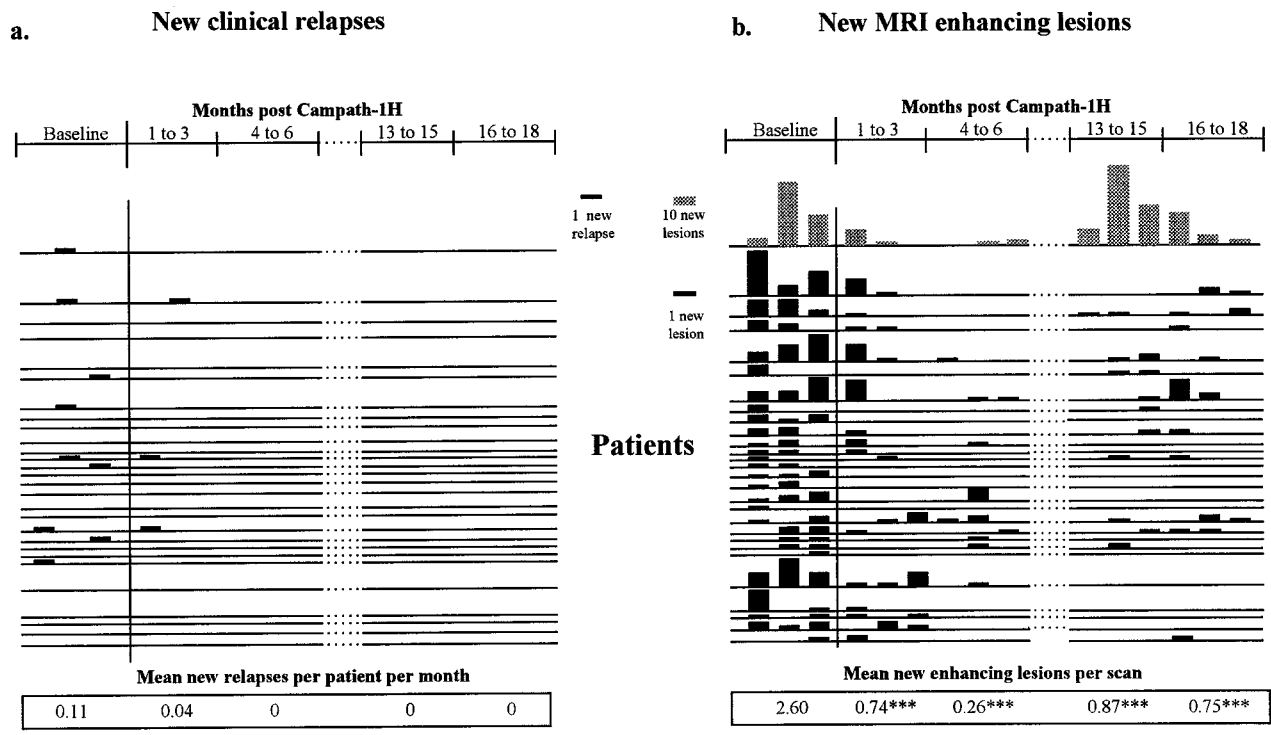


Fig 3. Disease activity in 28 with multiple sclerosis after Campath-1H treatment, shown as new clinical relapses (see text for definition) (a) and the number of new gadolinium-enhancing magnetic resonance imaging lesions in each patient (b). The length of the columns indicates the duration of observation for each individual. *** $p < 0.001$.

points when the EDSS is >5.5), 15 of 28 patients deteriorated in the 18 months after treatment (Fig 4a). Therefore, some patients continued to acquire disability, not by the accumulation of new lesions, but by progression of existing deficits. The group of patients with progressive disability had a higher MRI inflammatory load before treatment with Campath-1H ($p < 0.001$) compared with those with stable disability. Although there was a small, but significant, difference in inflammatory load for the subsequent 18 months between patients with stable or progressive disability, the reduction in inflammation by Campath-1H was equivalent between the two groups of patients (see Fig 4b). This suggests that a mechanism other than active inflammation must explain progressive disability.

Fourteen of 25 patients during the study had evidence for increasing cerebral atrophy on MRI scan, above the 95% confidence intervals for measurement variation (data on 3 patients are not available). Ten of these patients had progressive disability, which was seen in only 3 of the patients with stable cerebral volumes ($p = 0.028$, $\chi^2 = 15.2$). The 13 patients with progressive disability had a smaller mean brain volume before treatment (Fig 5a; $p = 0.05$) and a significantly higher rate of volume loss compared with those with stable disability (-6.7 ml/yr compared with -0.7 ml/yr; $p = 0.009$). Cerebral atrophy in multiple sclerosis is

likely to be the result of several processes, including axonal loss, demyelination, and gliosis. Because a fall in NAA may be used as a marker of axonal loss (see Discussion), we explored the pathological basis for the increasing cerebral atrophy in this cohort by MRI spectroscopy for NAA in 6 patients selected as having progressive disability and cerebral atrophy compared with 6 with stable disability and cerebral volume. There was a significant correlation between NAA and cerebral volume at 18 months ($r = 0.73$, $p < 0.01$; see Fig 5b), suggesting that axonal loss was an important cause of cerebral atrophy in this cohort. No clinical parameter before treatment discriminated patients who subsequently developed progressive cerebral atrophy; neither did treatment of the first dose effect, nor the addition of monoclonal anti-CD4 antibody, influence clinical progression or cerebral atrophy after Campath-1H.

Discussion

Our study illustrates the difficulty that arises in explaining the clinical manifestations and course of multiple sclerosis solely on the basis of demyelination and remyelination. Pathological, radiological, and electrophysiological studies suggest that the earliest events in the pathogenesis are inflammation and demyelination. It has previously been assumed that symptoms arise from conduction block caused by demyelination alone.

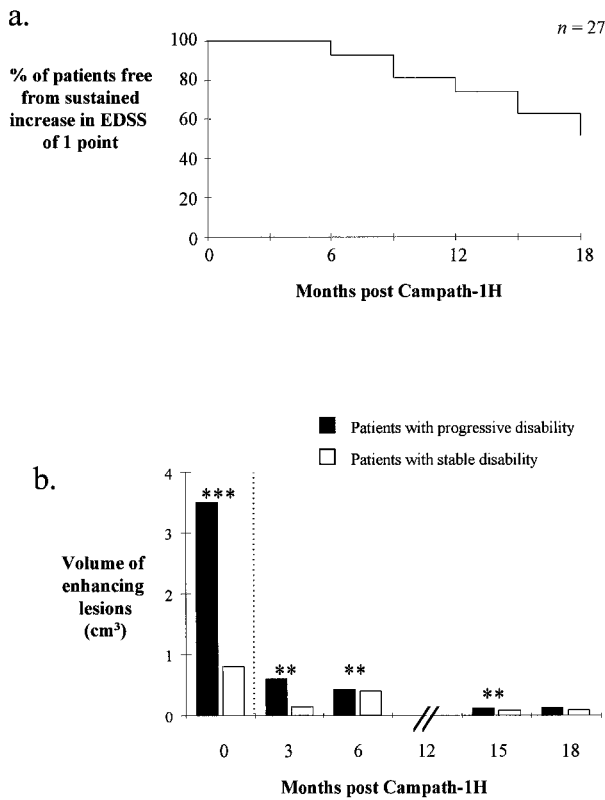


Fig 4. (a) The probability of remaining free from clinical progression after Campath-1H. (b) the volume of magnetic resonance imaging gadolinium-enhancing lesions in patients who remained clinically stable (open columns) and those who had significant progression (filled columns) after treatment. *** $p < 0.001$, ** $p < 0.01$.

However, evidence exists for a direct role of inflammation in symptom production; visual evoked potentials in acute optic neuritis are both reduced in amplitude and increased in latency, indicating conduction block and demyelination, and there is gadolinium enhancement on MRI scan, implying active inflammation; after enhancement ceases, the amplitude of visual evoked potentials returns to normal, suggesting restoration of conduction, but the latency of the visual evoked potential remains delayed, implying persistent demyelination.¹²

We observed a transient rehearsal of previous or current symptoms during the first dose of Campath-1H. We suggested, because of the rapidity of this effect and its lack of residual deficit, that it is caused by conduction block at sites of previous demyelination; this claim is supported by electrophysiological data presented in our previous work.⁴ The effect is reminiscent of the augmentation of symptoms dependent on impaired conduction through demyelinated pathways with local changes in temperature and calcium ion concentration.^{13,14} The mediator for this first dose effect is un-

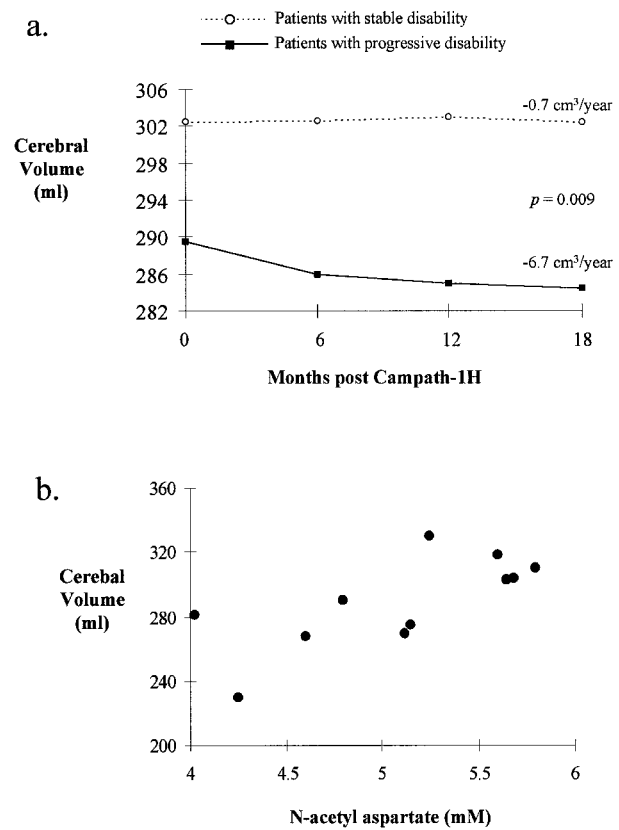


Fig 5. (a) The cerebral volume of patients who remained clinically stable (dotted line) and those who had significant progression (solid line) after Campath-1H. (b) The relationship between cerebral volume and N-acetyl aspartate in a subgroup of 12 patients from the whole cohort.

identified; we have excluded free TNF- α although it remains possible that membrane bound TNF- α is inadequately neutralized by soluble TNF- α receptor. Experimental studies implicate nitric oxide¹⁵ as a potential cause. Whatever its identity, it seems reasonable to suggest that it is induced by inflammation as well as by lymphocyte depletion after Campath-1H. Thus, the mechanism of acute relapse in multiple sclerosis may include fully reversible physiological conduction block caused by mediators of inflammation as well as demyelination. This explains why recovery from relapse may occur more rapidly than can be explained by remyelination and why old symptoms are frequently rehearsed in patients with multiple sclerosis.

A potential criticism of our study protocol is that short-term manipulation of the first dose effect of Campath-1H confounded the effect of monoclonal antibodies on multiple sclerosis disease activity. But it has been demonstrated repeatedly that methylprednisolone does not alter the long-term course of multiple sclerosis.^{16,17} There is less experience with TNF- α blockade in multiple sclerosis, save for the report that it tran-

siently worsened markers of disease activity in 2 patients,¹⁸ but the experience from rheumatoid arthritis is that repeated courses of treatment are required to alter the natural history.^{19,20} Thus, we felt confident in disregarding variations in the initial treatment protocols in analyzing the long-term data. Furthermore, no differences emerged between those patients treated with or without the anti-CD4 antibody and so we report the results as a single cohort of individuals receiving Campath-1H, using a crossover design. The radiological data suggest that new gadolinium-enhancing MRI lesion formation is profoundly reduced by a single 5-day pulse of Campath-1H, maximally at 3 to 6 months after treatment and remains significantly suppressed for at least 18 months, to similar levels as those seen in patients treated continuously with IFN- β .²¹⁻²³ Although this study did not include controls, comparison with a natural history study of the rate of new lesion formation in untreated patients with secondary progressive multiple sclerosis²⁴ leaves little doubt that the extent of suppression of new enhancing lesions after Campath-1H is a real treatment effect and not simply regression to mean.

Gadolinium enhancement in MRI of the brain has been shown experimentally,²⁵ in one human postmortem study,²⁶ and in a recent pathological study,²⁷ to be associated with inflammation. We use this term to include the accumulation of cells, soluble mediators, and water in active lesions and do not seek to distinguish these elements in formulating ideas on the pathogenesis of multiple sclerosis. Taken with the clinical evidence that new neurological sites are not involved after treatment, this supports the current consensus that inflammation, and thereby demyelination, are the pathological mechanisms underlying neurological relapses in multiple sclerosis. But despite the substantial reduction of MRI disease activity and abolition of new clinical relapses, half our patients continued to experience a deterioration in disability after Campath-1H. Those who deteriorated clinically after Campath-1H had a significantly greater pretreatment inflammatory load, measured by MRI; they had smaller cerebral volumes; and clinical progression correlated significantly with additional cerebral atrophy. In a similar manner, progressive cerebral atrophy was noted in half of the treated patients after monoclonal anti-CD4 antibody treatment of multiple sclerosis.¹⁰ However, unlike Campath-1H, this agent had no impact on gadolinium-enhancing lesions.²⁸ This suggests that a dissociation exists between the mechanisms underlying cerebral atrophy and gadolinium-enhancing lesions. Analysis of NAA concentration in a subgroup of patients casts light on the cause of the progressive cerebral atrophy seen in some patients after Campath-1H. NAA is an amino acid that has been shown, in experimental studies on neonatal rats, to be contained almost ex-

clusively in neurons.^{29,30} Although NAA is present in oligodendrocyte progenitor cells,³¹ these are only present in very small numbers in healthy adult human brain and are thus unlikely to contribute significantly to the concentration of NAA. A postmortem study in patients with multiple sclerosis has confirmed an absolute reduction of NAA from chronic multiple sclerosis lesions³² and there is now extensive literature confirming a reduction of NAA in several neurological diseases characterized by neuronal loss.³³⁻³⁵ Thus, a fall in NAA concentration is associated with axonal degeneration. Our study provides additional clinical insight into the relationship between axonal degeneration and inflammation in multiple sclerosis; axonal degeneration is conditioned by a high inflammatory load but proceeds even when inflammation has subsequently been suppressed. In the absence of serial gadolinium-enhanced images of the entire neuraxis, we cannot exclude the possibility that progression in this cohort was associated with active spinal cord inflammation. But we discount this interpretation, given the magnitude (>90%) suppression of cerebral magnetic resonance activity and the good correlation that exists between the dynamics of brain and cord inflammation.³⁶

Several potential mechanisms can be offered for the progression of axonal degeneration in the absence of active inflammation. It may be a delayed expression of axonal damage sustained during the acute inflammatory phase.^{37,38} In contrast, it may be a consequence of immune deviation toward the Th2 phenotype induced by Campath-1H as evidenced by down-regulation of the expression of IFN- γ by peripheral blood mononuclear cells for at least 12 months, a progressive increase in B-cell numbers, and autoimmune hyperthyroidism in one-third of patients treated for multiple sclerosis (Coles and associates, unpublished data). As part of this apparent promotion of antibody-mediated autoimmunity, anti-neuronal antibodies may have developed but we found none (data not shown). Last, axonal degeneration may be a consequence of demyelination, either through loss of trophic support from the oligodendrocyte³⁹⁻⁴¹ or secondary to altered electrical conduction.⁴²

We conclude that three processes underlie the clinical course of multiple sclerosis. The pivotal event is inflammation from which follow, in sequence, demyelination and axon degeneration. Inflammation promotes demyelination, which is responsible for many clinical features of each new relapse, but other components of the acute deficit result from fully reversible conduction block induced directly by inflammatory mediators. It is well known that any transient increase in the synthesis of inflammatory mediators coinciding with infections may cause a rapid and transient rehearsal of previously experienced symptoms or signs in

patients with multiple sclerosis, as a result of oscillations in conduction through pathways with a reduced safety factor for propagation of the nerve impulse. Persistent demyelination is associated with clinical progression and brain atrophy caused by axon degeneration; this occurs in the absence of active inflammation but is conditioned by the amount of prior disease activity. The implication of this analysis, derived from clinical and radiological observations of our patients treated by using Campath-1H but supported by observations gathered from a range of pathological and experimental studies, is that antiinflammatory therapies will best prevent the progression of disability if given early in the course of multiple sclerosis and before the cascade of events that leads to axon degeneration has been irretrievably established.

Dr Coles is an MRC Clinical Training Fellow and some aspects of the work were supported by a grant from MuSTER. Campath-1H is a registered trademark of Leukosite Inc.

We are grateful to John Deighton and Simon McHugh for technical assistance in ELISA development; to Jenny Phillips and members of the Therapeutic Antibody Centre for producing the therapeutic antibodies used in this study, funded by the MRC and the Wellcome Foundation Ltd; to D. S. Yoo for developing the software to analyze brain atrophy; and to Jackie Deans for invaluable assistance in patient management. The Multiple Sclerosis Society provided the MRI scanner.

References

1. Benjamin RJ, Waldmann H. Induction of tolerance by monoclonal antibody therapy. *Nature* 1986;320:449–451
2. Qin S, Cobbold SP, Pope H, et al. “Infectious” transplantation tolerance. *Science* 1993;259:974–977
3. Moreau T, Thorpe J, Miller D, et al. Preliminary evidence from magnetic resonance imaging for reduction in disease activity after lymphocyte depletion in multiple sclerosis [published erratum. *Lancet* 1994;344:486]. *Lancet* 1994;344:298–301
4. Moreau T, Coles A, Wing M, et al. Transient increase in symptoms associated with cytokine release in patients with multiple sclerosis. *Brain* 1996;119:225–237
5. Charpentier B, Hiesse C, Lantz O, et al. Evidence that antihuman tumor necrosis factor monoclonal antibody prevents OKT3-induced acute syndrome. *Transplantation* 1992;54:997–1002
6. Ferran C, Dy M, Sheehan K, et al. Cascade modulation by anti-tumor necrosis factor monoclonal antibody of interferon-gamma, interleukin 3 and interleukin 6 release after triggering of the CD3/T cell receptor activation pathway. *Eur J Immunol* 1991;21:2349–2353
- 6a. Paolillo A, Coles A, Molyneux P, et al. Quantitative MRI in patients with secondary progressive MS treated monoclonal antibody, Campath-1H. *Neurology* (In press)
7. Kurtzke JF. Rating neurologic impairment in multiple sclerosis: an expanded disability status scale (EDSS). *Neurology* 1983;33:1444–1452
8. Branch DR, Shah A, Guilbert LJ. A specific and reliable bioassay for the detection of femtomolar levels of human and murine tumor necrosis factors. *J Immunol Methods* 1991;143:251–261

9. Hay H, Cohen J. Studies on the specificity of the L929 cell bioassay for the measurement of tumour necrosis factor. *J Clin Lab Immunol* 1989;29:151–155
10. Losseff NA, Wang L, Lai HM, et al. Progressive cerebral atrophy in multiple sclerosis: a serial MRI study. *Brain* 1996;119:2009–2019
11. Poser CM, Paty DW, Scheinberg L, et al. New diagnostic criteria for multiple sclerosis: guidelines for research protocols. *Ann Neurol* 1983;13:227–231
12. Youl BD, Turano G, Miller DH, et al. The pathophysiology of acute optic neuritis: an association of gadolinium leakage with clinical and electrophysiological deficits. *Brain* 1991;114:2437–2450
13. Davis FA, Schauff CL, Reed BJ, Kesler RL. Experimental studies of the effects of extrinsic factors on conduction in normal and demyelinated nerve. 1. Temperature. *J Neurol Neurosurg Psychiatry* 1976;39:442–448
14. Schauff CL, Davis FA, Sack DA, et al. Neuroelectric blocking factors in human and animal sera evaluated using the isolated frog spinal cord. *J Neurol Neurosurg Psychiatry* 1976;39:680–685
15. Redford EJ, Kapoor R, Smith KJ. Nitric oxide donors reversibly block axonal conduction: demyelinated axons are especially susceptible. *Brain* 1997;120:2149–2157
16. Frequin ST, Lamers KJ, Barkhof F, et al. Follow-up study of MS patients treated with high-dose intravenous methylprednisolone. *Acta Neurol Scand* 1994;90:105–110
17. Milligan NM, Newcombe R, Compston DA. A double-blind controlled trial of high dose methylprednisolone in patients with multiple sclerosis: 1. Clinical effects. *J Neurol Neurosurg Psychiatry* 1987;50:511–516
18. Van Oosten BW, Barkhof F, Truyen L, et al. Increased MRI activity and immune activation in two multiple sclerosis patients treated with the monoclonal anti-tumor necrosis factor antibody cA2. *Neurology* 1996;47:1531–1534
19. Elliott MJ, Maini RN, Feldmann M, et al. Repeated therapy with monoclonal antibody to tumour necrosis factor alpha (cA2) in patients with rheumatoid arthritis. *Lancet* 1994;344:1125–1127
20. Elliott MJ, Maini RN, Feldmann M, et al. Randomised double-blind comparison of chimeric monoclonal antibody to tumour necrosis factor alpha (cA2) versus placebo in rheumatoid arthritis. *Lancet* 1994;344:1105–1110
21. Stone LA, Frank JA, Albert PS, et al. Characterization of MRI response to treatment with interferon beta-1b: contrast-enhancing MRI lesion frequency as a primary outcome measure. *Neurology* 1997;49:862–869
22. Rudge P, Miller D, Crimlisk H, Thorpe J. Does interferon beta cause initial exacerbation of multiple sclerosis? *Lancet* 1995;345:580 (Letter)
23. Stone LA, Albert PS, Smith ME, et al. Changes in the amount of diseased white matter over time in patients with relapsing-remitting multiple sclerosis. *Neurology* 1995;45:1808–1814
24. Molyneux PD, Filippi M, Barkhof F, et al. Correlations between monthly enhanced MRI lesion rate and changes in T2 lesion volume in multiple sclerosis. *Ann Neurol* 1998;43:332–339
25. Hawkins CP, Mackenzie F, Tofts P, et al. Patterns of blood-brain barrier breakdown in inflammatory demyelination. *Brain* 1991;114:801–810
26. Katz D, Taubenberger JK, Cannella B, et al. Correlation between magnetic resonance imaging findings and lesion development in chronic, active multiple sclerosis. *Ann Neurol* 1993;34:661–669
27. Bruck W, Bitsch A, Kolenda H, et al. Inflammatory central

- nervous system demyelination: correlation of magnetic resonance imaging findings with lesion pathology. *Ann Neurol* 1997;42:783–793
28. Van Oosten BW, Lai M, Hodgkinson S, et al. Treatment of multiple sclerosis with the monoclonal anti-CD4 antibody cM-T412; results of a randomized, double-blind, placebo-controlled, MR-monitored phase II trial. *Neurology* 1997;49:351–357
 29. Birken DL, Oldendorf WH. *N*-Acetyl-L-aspartic acid: a literature review of a compound prominent in ¹H-NMR spectroscopic studies of the brain. *Neurosci Biobehav Rev* 1989;13:23–31
 30. Urenjak J, Williams SR, Gadian DG, Noble M. Proton nuclear magnetic resonance spectroscopy unambiguously identifies different cell types. *J Neurosci* 1993;13:981–989
 31. Scolding NJ, Rayner PJ, Sussman J, et al. A proliferative adult human oligodendrocyte progenitor. *Neuroreport* 1995;6:441–445
 32. Davies SEC, Newcombe J, Williams SR, et al. High resolution proton NMR spectroscopy of multiple sclerosis lesions. *J Neurochem* 1995;64:742–748
 33. Chong WK, Sweeney B, Wilkinson ID, et al. Proton spectroscopy of the brain in HIV infection: correlation with clinical, immunologic and MR imaging findings. *Radiology* 1993;188:119–124
 34. Gideon P, Henriksen O, Sperling B, et al. Early time course of *N* acetyl aspartate, creatinine and phosphocreatine and compounds containing choline in the brain after acute stroke: a proton magnetic resonance study. *Stroke* 1992;23:1566–1572
 35. Van der Knaap MS, Van der Grond J, Luyten PR, et al. ¹H and ³¹P magnetic resonance spectroscopy of brain degenerative cerebral disorders. *Ann Neurol* 1992;31:202–211
 36. Thorpe JW, Kidd D, Moseley IF, et al. Serial gadolinium-enhanced MRI of the brain and spinal cord in early relapsing-remitting multiple sclerosis. *Neurology* 1996;46:373–378
 37. Ferguson B, Matyszak MK, Esiri MM, Perry VH. Axonal damage in acute multiple sclerosis lesions. *Brain* 1997;120:393–399
 38. Trapp BD, Peterson J, Ransohoff RM, et al. Axonal transection in the lesions of multiple sclerosis. *N Engl J Med* 1998;338:278–285
 39. Colello RJ, Pott U, Schwab ME. The role of oligodendrocytes and myelin on axon maturation in the developing rat retinofugal pathway. *J Neurosci* 1994;14:2594–2605
 40. Kaplan MR, Meyer Franke A, Lambert S, et al. Induction of sodium channel clustering by oligodendrocytes. *Nature* 1997;386:724–728
 41. Meyer Franke A, Kaplan MR, Pfrieger FW, Barres BA. Characterization of the signaling interactions that promote the survival and growth of developing retinal ganglion cells in culture. *Neuron* 1995;15:805–819
 42. Pfrieger FW, Barres BA. Synaptic efficacy enhanced by glial cells in vitro. *Science* 1997;277:1684–1687